



PRESENTING CLINICAL SIGNS

History: Recheck degenerative valve disease. Slowing down. Sedated for exam with acepromazine and butorphanol.

DATE

8/31/21

ECHOCARDIOGRAPHIC FINDINGS

2D, M-mode, and Doppler study. This exam is compared to the one performed 2/24/21.

PERFORMED BY:

Dr. Brian Barnes

INTERPRETED BY

Keith Blass, DVM,
MS, DACVIM
(Cardiology)

Left atrial size is normal. The mitral valve leaflets are mildly thickened, and a mild jet of eccentric mitral regurgitation is present. Left ventricular dimensions are normal, as is left ventricular systolic function. The aorta and aortic valve appear normal, though very mild aortic insufficiency is present. Right atrial and right ventricular dimensions are normal. The tricuspid valve leaflets are mildly thickened, and a mild jet of tricuspid regurgitation is present. TR velocity does not suggest the presence of pulmonary hypertension. The pulmonary artery and pulmonic valve appear normal, though trace pulmonic insufficiency is present. No pericardial effusion or cardiac masses are seen.

ECG during echo: Sinus arrhythmia

PATIENT

Zillah Tyler

SPECIES

Canine

LA -24.6 mm (prev. 24.7 mm)
LVIDd - 24.5 mm (prev. 24.8 mm)
LVIDs - 16.3 mm (prev. 15.3 mm)
FS - 32.6% (prev. 38%)
LVOT- 1.31 m/s (prev. 1.35 m/s)
RVOT - 0.95 m/s (prev. 0.69 m/s)
TR -2.50 m/s (prev. 2.40 m/s)

ASSESSMENT/RECOMMENDATIONS

Degenerative mitral and tricuspid valve disease

BREED

Papillon Mix

This examination demonstrates no progression of Zillah's valvular diseases over the past 6 months. As such, her valvular diseases still appear to be well-compensated, and Zillah's current risk for the development of clinical signs secondary to them still appears to be low.

SEX

FS

No therapy is recommended at this stage of Zillah's valvular diseases.

A recheck echocardiogram is recommended in 6 months to monitor for disease progression.

AGE

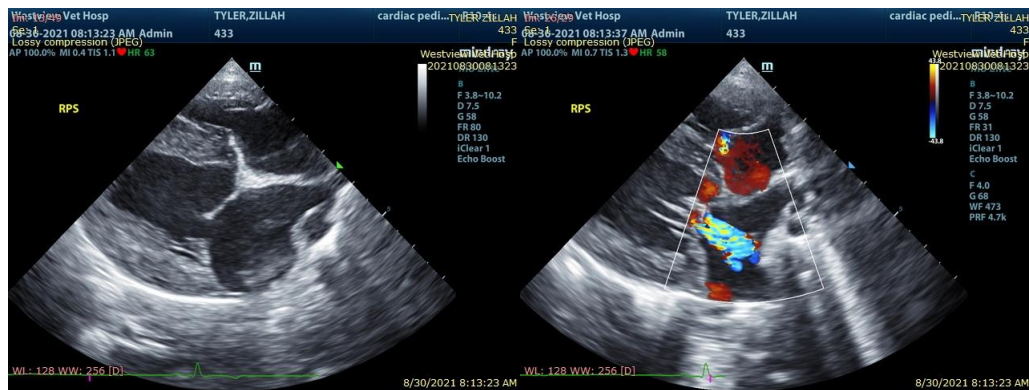
14 y

WEIGHT

6.75 kg

HOSPITAL NAME

Westview VH



REFERRING VET

Dr. Barnes

The information and recommendations provided are based on the images presented by the



referring veterinarian. No evaluation can be communicated regarding pathology that was not visible in the image/video clips provided.

DATE

8/31/21

Thank you for this referral. If the clinical or image interpretation does not parallel your findings or if I can be of any further assistance please contact me.

PERFORMED BY: Keith Blass, DVM, MS, DACVIM (Cardiology)

KeithBlass@gmail.com
631-804-5754

Dr. Brian Barnes

INTERPRETED BY

Keith Blass, DVM,
MS, DACVIM
(Cardiology)

PATIENT

Zillah Tyler

SPECIES

Canine

BREED

Papillon Mix

SEX

FS

AGE

14 y

WEIGHT

6.75 kg

HOSPITAL NAME

Westview VH

REFERRING VET

Dr. Barnes